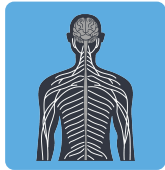


TOPIC: TETANUS



Tetanus

Bacterial

GRAM ____

SHAPE: Endospore forming ____




(CDC, 1995).

CAUSE

Clostridium tetani (*C. tetani*).

- ◆ _____ → thrives in deep, improperly cleaned wounds.
- ◆ Cell death releases _____ tetanospasmin (tetanus toxin).
 - Tetanospasmin acts on _____ of the brain stem and spinal cord.
 - Blocks release of _____ neurotransmitters → muscles don't relax.
 - Respiratory spasms can be _____.

Charles Bell. (1809). *Tetanus Following Gunshot Wounds*. [Oil painting on canvas]. The Royal College of Surgeons of Edinburgh. GC.13842.



SPREAD

Bacteria from soil enters through a _____ wound.

SYMPTOMS

Uncontrolled, prolonged muscle spasms.

- ◆ Often beginning with jaw stiffness (_____) then spreading.
- ◆ Symptoms may begin days to _____ after injury.

DIAGNOSIS

Treatment based on symptoms & injury history, not formal diagnosis.

- ◆ _____, rigid muscles, spasms with _____ history.

TREATMENT

Treat both the toxin & bacteria: treatment does not _____ symptoms.

- ◆ Debridement: removing _____ and cleaning injury site.
- ◆ Administer immunization/booster depending on vaccine status.
- ◆ *Tetanus Immune Globulin* (TIG): if symptomatic or unknown _____ status.
- ◆ Antibiotics: metronidazole if symptomatic.

IMMUNITY

_____ vaccine: booster can be given w/in 24-48 hours of

- ◆ Dtap: _____ vaccine for diphtheria, tetanus, & pertussis.
- ◆ Tdap: adult _____ vaccine for tetanus, diphtheria & pertussis.
- ◆ Td: adult booster vaccine for tetanus & diphtheria.

TOPIC: TETANUS

References:

Bell, C. (1809). *Tetanus Following Gunshot Wounds*. [Oil on canvas] The Royal College of Surgeons of Edinburgh. GC.13842. https://commons.wikimedia.org/wiki/File:Opisthotonus_in_a_patient_suffering_from_tetanus_-_Painting_by_Sir_Charles_Bell_-_1809.jpg
(1995). [Photomicrograph of *Clostridium tetani* bacteria] Centers for Disease Control and Prevention. <https://phil.cdc.gov/Details.aspx?pid=6372>

EXAMPLE

Imagine that you are a doctor, and a patient comes to your office complaining of jaw stiffness. An examination shows that they have a small wound on their arm. The patient indicates that they were poked when dismantling an old, barbed wire fence a little over a week ago, drawing blood. The patient's history shows that they last received a tetanus booster about 15 years ago. What actions should you take with this patient? Briefly justify each action.

| Action | Justification |
|---------------|----------------------|
| 1. _____: | _____ |
| 2. _____: | _____ |
| 3. _____: | _____ |
| 4. _____: | _____ |

PRACTICE

To protect against tetanus, the tetanus vaccine contains which of the following?

- a) Attenuated virus.
- b) Bacterial RNA.
- c) Inactive toxin.
- d) Capsular polysaccharides.

PRACTICE

After which of the following events would an individual be most at risk for an infection from *C. tetani*?

- a) Eating a friend's home-canned vegetables.
- b) A deep puncture wound sustained during a crash while mountain biking.
- c) Being bitten by a stray dog.
- d) A small cut sustained while gardening with manure-based compost.